

Protocols and Best Practices for Treating Diaphragmatic Endometriosis

Camran Nezhat, Farr Nezhat, Ceaná Nezhat

Lately there have been many discussions reminding us of just how crucial it is to eradicate endometriosis as completely as possible. As a surgical imperative, this is actually a time-honored principle, one that has been observed since at least the late 19th and early 20th centuries, when progenitor pioneers like Marion Sims, Cullen, and Sampson found that patients were more likely to experience relief from symptoms when as much disease as possible was removed. Sims was so committed to this principle that he even used his own fingernails to “excise” endometriosis that was otherwise difficult to remove with the standard instruments of his day! (^{1, 2})

However, implicit in some of these narratives is the flawed assumption that endometriosis returns as a result of an incomplete and/or inadequate method of treatment (ie, ablation/excision) from a previous surgery,. While it’s certainly true that inexperienced surgeons might treat endometriosis inadequately, what’s equally true, if not more so, is the fact that endometriosis can recur despite the most thorough treatment possible. In other words, all the medical interventions in the world, by all the world’s greatest practitioners, cannot prevent endometriosis from returning in certain cases. Since these and other similar misconceptions about endometriosis have become rather prevalent lately, we thought it was a good time to bring these issues into the conversations.

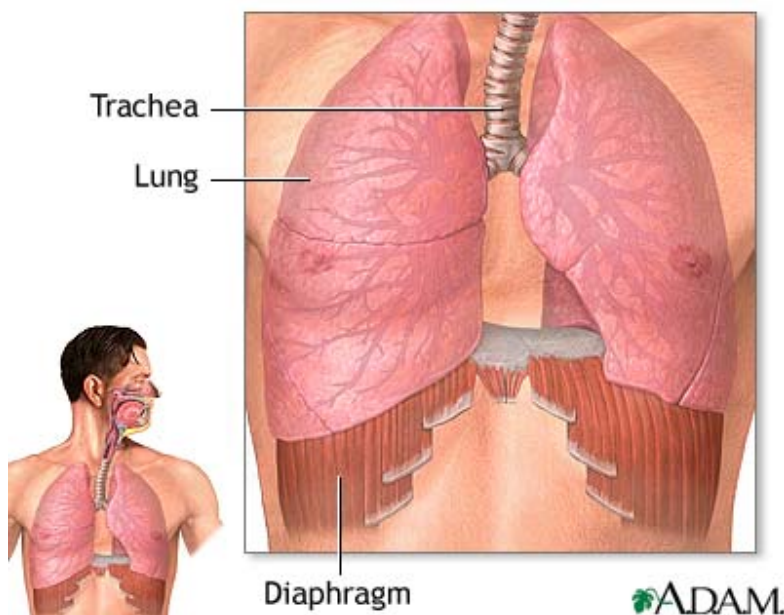
And, since we are on the topic of thoroughly treating endometriosis, we would like to add to the discussion the issue of diaphragmatic endometriosis, an extragenital form that actually is sometimes overlooked and left behind due to its propensity for hiding behind the liver and other structures of the upper abdomen. (³)

Quick overview of the diaphragm’s anatomical features

For patients or others who might want a quick anatomy refresher course, we thought the following review of the thoracic diaphragm’s anatomical features would be a good place to start. The most important muscle for human respiration, the diaphragm is a long and thin, convex organ located below the heart and lungs, attaching to the lower ribs, sternum and lumbar spine and forming the base of the thoracic cavity. Positioned as it is, it conveniently separates the chest cavity from the abdominal cavity. Lengthwise it ranges from 6 to 12 inches, while its thickness usually measures somewhere between one-quarter to one-eighth of an inch. With its symmetrical, lobe-like formation, the diaphragm’s right and left sides are distinctly demarcated (though still contiguous). For

this reason, many physicians refer to the two lobes as the right and left hemidiaphragms. The diaphragm's main innervating source is the phrenic nerve, which in turn is fed by the cervical nerves C3, C4, and C5. (Many of our physician friends will probably remember the mnemonic, "C-3, 4, 5, keep the diaphragm alive."). However, there are also two peripheral innervating sources called the intercostal and subcostal nerves, located at T5-T11 and T12, respectively.

Highly flexible, the diaphragm contracts and relaxes as breathing takes place. Specifically, when a person inhales the diaphragm and its intercostal muscles contract downward, thereby widening the thoracic cavity in which the lungs are contained. As a result, air fills the lungs through the mechanical process of suction. When a person exhales, the diaphragm and intercostal muscles relax, thereby mechanically forcing air out of the lungs.



Most Common Symptoms of Diaphragmatic Endometriosis

Symptomatic diaphragmatic endometriosis can manifest as shortness of breath (dyspnea), epigastric pain (upper GI), and pain in the chest (pleuritic), shoulder, and right or left upper quadrant (upper abdomen), all of which may or may not be cyclic. The rarer but more serious and potentially life-threatening conditions of catamenial pneumothorax, hemopneumothorax, chest wall lesions, and lung parenchyma can also cause similar symptoms and sometimes occur concomitantly with diaphragmatic endometriosis as a result of diaphragmatic defects caused by the necrotizing effects of endometriotic lesions. (^{4, 5}) Congenital defects or fenestration of the right

hemidiaphragm can also contribute to the development of diaphragmatic endometriosis, as well as in surrounding areas of the chest, lung, and pleural cavity. For these reasons, these conditions should be ruled out during any diagnostic investigations. Although rarer still, with fewer than 20 cases reported in the literature, liver endometriosis should also be a part of differential diagnoses, as it too can cause cyclic upper abdominal pain. (6,7)

The good news about diaphragmatic endometriosis is that after thorough surgical treatment, studies have found that it is far less likely to recur than other forms of the disease. (4) While most implants are superficial and cause no discomfort, others can be deeply infiltrating, including cases of full thickness infiltration. In one of our studies, 29% of our patients had deeply infiltrating implants. (8) In more serious cases like these, the lesions can cause multiple small perforations which need to be surgically repaired.

Although lesions can present with varying colors and morphologies, the most common form appear to be those which have a bluish cast to them, as demonstrated by Figure 1 below. However, others have reported purplish-red lesions.

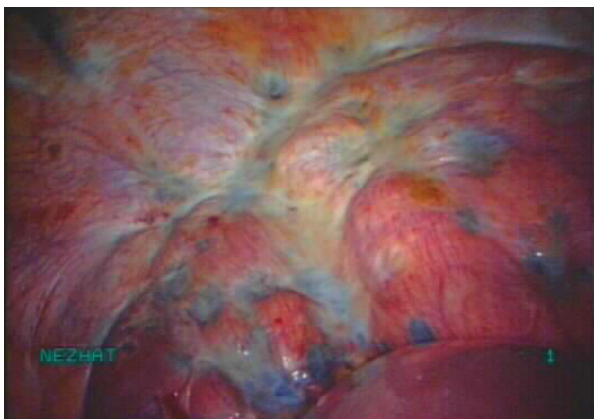


Figure 1: Bluish pigmented lesions most commonly reported form of diaphragmatic endometriosis

Other common features

As you've probably heard by now, most lesions occur on the right side, a propensity which many cite as the central supporting evidence for Sampson's retrograde menstruation theory of pathogenesis. However, lesions have been found on all parts of the diaphragm, such as its phrenic nerve, as well as adjacent structures. Sometimes lesions are bilateral, while others form on just one side. And, sometimes the majority of lesions present anteriorly, where they lie hidden behind the liver. Given such a wide

variation in locations, the entire diaphragm and adjacent areas must therefore be thoroughly investigated.

Preliminary steps for determining a treatment plan

For those who are not symptomatic but who have been diagnosed with any of these extragenital forms of endometriosis incidentally, some recommend to take an expectant approach with no further intervention, unless symptoms later occur.⁽⁹⁾ However, for those patients who are symptomatic, surgery has proven beneficial when other medical interventions have otherwise failed.^(7, 10, 11) If proceeding with surgery, however, one must take care to counsel patients well about their other options because injury can occur to the diaphragm, phrenic nerve, lungs, vessels, or heart. And, as with any other procedure, care should be individualized, taking into consideration the patient's goals, age, medical condition, etc, as well the practitioner's experience and availability of appropriate inter-disciplinary consultants.

A few key protocols in surgical management

While diaphragmatic endometriosis presents many unique challenges, we thought we would focus on just a few key protocols that we've relied on over the years to help us navigate through these especially tricky anatomical landscapes.

The first issues to address are concerns about access and visualization of the upper abdomen and the diaphragm's entire surface. We would like to urge our community to not let these particular concerns be reasons to resort to laparotomy, which is known to most likely cause the painful and potentially intestinal-obstructing thick vascular sorts of adhesions in more than 93% of cases.^(12, 13) By resorting to laparotomy, one treatable problem would be exchanged with another potentially disabling one.

To avoid all the headaches that laparotomies can come with, the first step is to consult with an endoscopic surgeon experienced in upper abdomen procedures. Surgeons with sufficient experience will be able to utilize several different techniques and devises to help obtain a clear view of the diaphragm and adjacent areas. For example, the patient's position can be changed during surgery, so that the diaphragm's surrounding organs fall away from it enough so that one can see parts that would be otherwise obscured. As well, surgeons can add more port holes (the tiny incisions in which the laparoscopes are inserted) in the upper abdomen so that better visualization can be obtained. More advanced surgeons can even rely on highly specialized techniques, such as resecting the falciform ligament or using the laparoscopes to gently move the liver and stomach away from the diaphragm so that it can be better visualized. In fact, we routinely deploy these and other minimally invasive strategies in oncological gynecology, when it's often

necessary to debulk diaphragmatic metastatic disease which sometimes requires partial resections of the diaphragm and mesh placements. ⁽¹⁴⁾

As for excisional techniques, it depends on many factors, including the nature of the lesion itself. However, the most essential consideration is complete removal of endometriosis. Randomized controlled studies have shown that thorough eradication of the disease is the only variable consistently associated with any measureable reductions in pain and recurrence rates. ^(15, 16) And, contrary to common misconceptions, it makes no difference which technique is utilized; vaporization, ablation, hydrodissection, and scissors excisions have all proven to be effective methods. There are also many devices that can be used for complete excision, all of which have their own advantages and disadvantages. For example, compared to monopolar instruments, the laser has proven especially safe and useful for excising or otherwise eradicating both superficial and deeply infiltrating endometriosis, since it poses no danger of having its energy heat arc out in erratic ways. As a result, laser surgeries are associated with substantially fewer incidence of inadvertent injury to surrounding healthy tissue or organs. ^(17, 18, 19)

(The following video of laparoscopic diaphragmatic stripping for ovarian cancer demonstrates several techniques which, even though they're applied here in an oncological setting, nevertheless can be used for treating diaphragmatic endometriosis as well: <http://www.youtube.com/watch?v=jMXfRW-Whfc>)

Of course, surgical outcomes ultimately depend entirely on the skill and experience of the surgeon. This is especially true for those who specialize in treating endometriosis, a field of such complexity and ever-changing paradigms that the only hope we have for staying ahead of such a fast-moving curve is to continuously advance our knowledge in the latest surgical tools and techniques. The availability of proper instrumentation has also proven to be critical, for no matter how great of a pianist you are or want to be, you can't play if you don't have a piano or if the one you've got is utterly out of tune.

Postoperative medical care depends on whether patients are planning to conceive. For those wishing to become pregnant, there are no further postoperative medical interventions, other than the routine postoperative care and perhaps ART treatments or the like. For patients who are not planning to conceive, they may continue with some sort of hormonal suppressive treatment.

Collaboration with other sub-specialists is crucial

All of these protocols will prove nearly meaningless, however, without the element of multi-discipline collaboration, especially critical for treating such a multi-organ, systemic disorder as endometriosis. For example, even though we were the first to report on the laparoscopic treatment of liver endometriosis and have to our knowledge performed more of these surgeries than any other surgeon or institute, after over 3 decades of experience we have had only 3 such cases. For this reason, we've always advocated seeking out collaboration with experts from other fields. The same goes for endometriosis of the lungs, chest wall, and diaphragm, which collectively have accounted for no more than 40 of our cases over the years. Again, even though these 40 cases represent the first and largest number ever treated laparoscopically, it's still a comparatively small volume relative to the other types of surgeries we routinely perform. Given the rarity of such cases, collaboration with other sub-specialists is therefore an absolute imperative for the safety and well-being of patients.

We hope we've been able to provide some helpful perspectives on some of gynecology's most complex and contested issues. For further reading on these subjects, please see our list of references below.

REFERENCES

¹ Nezhat C. *Nezhat's History of Endoscopy: A Historical Analysis of Endoscopy's Ascension since Antiquity*. Tuttlingen, Germany: Endo-Press; 2011.

² Nezhat C. Pelvic pain, infertility, endometriosis: Old diseases, old treatments. *Fertil Steril*. In press.

³ Nezhat, Camran; Nicoll, Linda M; Bhagan, Lisa; Huang, Jian Qun; Bosev, Dorian; Hajhosseini, Babak; Beygui, Ramin E. Endometriosis of the diaphragm: four cases treated with a combination of laparoscopy and thoracoscopy. *Journal of Minimally Invasive Gynecology*. 2009; 16(5):573-80.

⁴ Nezhat C, et al. Bilateral Thoracic Endometriosis Affecting the Lung and Diaphragm - Case Report. In press. *JSLs*.

⁵ Endometriosis: Science and Practice. Linda C. Giudice, MD, Johannes L. H. Evers, David L. Healy.

⁶ Nezhat, C. et al. Laparoscopic management of hepatic endometriosis: report of two cases and review of the literature. *Journal of Minimally Invasive Gynecology* 12, 196-200 (2005).

⁷ Nezhat F, Nezhat C, Levy JS. Laparoscopic Treatment of Symptomatic Diaphragmatic Endometriosis: A Case Report. *Fertil Steril*, Vol. 58, No. 3, Pp: 614-616, 1992.

⁸ Nezhat's Operative Laparoscopy, 3rd ed. Cambridge Press. 2005. p 289-291.

-
- ⁹ Falcone T, Lebovic DL. Clinical Management of Endometriosis. *Obstet Gynecol.* 2011;118(3):691-705.
- ¹⁰ Nezhat, C. C., Seidman, D. D. S., Nezhat, F. F. & Nezhat, C. C. Laparoscopic surgical management of diaphragmatic endometriosis. *Fertility and Sterility* 69, 1048-1055 (1998).
- ¹¹ Mangal, R. R., Taskin, O. O., Nezhat, C. C. & Franklin, R. R. Laparoscopic vaporization of diaphragmatic endometriosis in a woman with epigastric pain: a case report. *Journal of reproductive medicine* 41, 64-66 (1996).
- ¹² Parker MC, Ellis H, Moran BJ, Thompson JN, Wilson MS, Menzies D, McGuire A, Lower AM, Hawthorn RJS, O'Brien F, et al. Postoperative adhesions: Ten-year follow-up of 12,584 patients undergoing lower abdominal surgery. *Diseases of the Colon & Rectum.* 2001; 44(6):822-9.
- ¹³ Redwine DB. Diaphragmatic endometriosis: diagnosis, surgical management, and long-term results of treatment. *Fertil Steril.* 2002; 77(2):288-96.
- ¹⁴ Nezhat FR, DeNoble SM, Liu CS, Cho JE, Brown DN, Chuang L, Gretz H, Saharia P. The safety and efficacy of laparoscopic surgical staging and debulking of apparent advanced stage ovarian, fallopian tube, and primary peritoneal cancers. *JSLs.* 2010 Apr-Jun;14(2):155-68.
- ¹⁵ Healey M, Ang C, Cheng C. Surgical treatment of endometriosis: a prospective randomized double-blinded trial comparing excision and ablation. *Fertil Steril* 2010; 94:2536-40.
- ¹⁶ Wright J, Lotfallah H, Jones K, Lovell D. A randomized trial of excision versus ablation for mild endometriosis. *Fertil Steril.* 2005; 83(6):1830-6.
- ¹⁷ Sutton CJ, Pooley AS, Ewen SP, Haines P. Follow-up report on a randomised controlled trial of laser laparoscopy in the treatment of pelvic pain associated with minimal to moderate endometriosis. *Fertil Steril* 1997; 68: 1070-4.
- ¹⁸ Luciano AA, Whitman GF, Maier DB, Randolph JF, Maenza RM: A comparison of thermal injury, healing patterns and postoperative adhesion formation following CO2 laser and electromicrosurgery. *Fertil Steril.*1987;48:1025-1029.
- ¹⁹ T, Vilos GA: A comparison between laser surgery and electrosurgery for bilateral hydrosalpinx. *Fertil Steril.* 1985; 44: 846.